

## #ASEchoJC Twitter Chat

Tuesday, December 19, 2023 – 8 PM ET

- [American Society of Echocardiography COVID-19 Statement Update: Lessons Learned and Preparation for Future Pandemics](#) (JASE, November 2023)

### Authors:

- James N. Kirkpatrick, MD, FASE (@Kirkpatj1)
- Madhav Swaminathan, MD, FASE (@mswami001)
- David H. Wiener, MD, FASE (@DavidWienerMD)

### Moderators:

- Enrique Garcia-Sayan, MD, FASE (@EGarciaSayan)
- Nadeen N. Faza, MD, FASE (@NadeenFaza)

### Introduction and Welcome:

@EGarciaSayan: Welcome to tonight's #ASEchoJC on the new #COVID19 guideline update. Thrilled to have guest authors @Kirkpatj1 @mswami001 @DavidWienerMD & co-moderator @NadeenFaza join us.

- ✓ Get ready to comment, ask questions, or just follow along
- ✓ Remember to use #ASEchoJC in all your posts

## GUIDELINES AND STANDARDS

### American Society of Echocardiography COVID-19 Statement Update: Lessons Learned and Preparation for Future Pandemics

Check for updates

James N. Kirkpatrick, MD, FASE (Chair), Madhav Swaminathan, MD, FASE (Co-Chair), Adeyinka Adedipe, MD, Enrique Garcia-Sayan, MD, FASE, Judy Hung, MD, FASE, Noreen Kelly, MD, FASE, Smadar Kort, MD, FASE, Sherif Naguib, MD, FASE, Kian Keong Poh, MD, FASE, Aarti Sarwal, MD, G. Monet Strachan, ACS, RDCS, FASE, Yan Topilsky, MD, Cathy West, MSc, AMS, FASE, and David H. Wiener, MD, FASE, Seattle, Washington; Durham, Charlotte, and Winston-Salem, North Carolina; Houston, Texas; Boston, Massachusetts; Stony Brook, New York; Singapore; San Francisco, California; Tel-Aviv, Israel; London, United Kingdom; and Philadelphia, Pennsylvania

The COVID-19 pandemic has evolved since the publication of the initial American Society of Echocardiography (ASE) statements providing guidance to echocardiography laboratories. In light of new developments, the ASE convened a diverse, expert writing group to address the current state of the COVID-19 pandemic and to apply lessons learned to echocardiography laboratory operations in future pandemics. This statement addresses important areas specifically impacted by the current and future pandemics: (1) indications for echocardiography, (2) application of echocardiographic services in a pandemic, (3) infection/transmission mitigation strategies, (4) role of cardiac point-of-care ultrasound/critical care echocardiography, and (5) training in echocardiography. (J Am Soc Echocardiogr 2023;36:1127-39.)

**Keywords:** Echocardiography, COVID-19, Triage, POCUS, Imaging, Training

**ASE JOURNAL CLUB ON X**  
(Formerly known as Twitter Journal Club)

**ASE**  
AMERICAN SOCIETY OF  
ECHOCARDIOGRAPHY  
*Sound Saves Lives*

**Tuesday, Dec. 19, 2023**  
**8:00 to 9:00 PM (ET)**

JOIN THE DISCUSSION ON:

**American Society of Echocardiography COVID-19 Statement Update: Lessons Learned and Preparation for Future Pandemics**

Guest Authors James N. Kirkpatrick, MD, FASE (@Kirkpatj1), Madhav Swaminathan, MD, FASE (@mswami001), and David H. Wiener, MD, FASE (@DavidWienerMD) will join ASE Journal Club on X Moderators Enrique Garcia-Sayan, MD, FASE (@EGarciaSayan) and Nadeen N. Faza, MD, FASE (@NadeenFaza)

**Earn CME!**  
1 AMA PRA Category 1 Credit\*

The ASE Journal Club on X (Formerly known as Twitter Journal Club) will answer your questions! Follow @ASE360 and use hashtag #ASEchoJC for all tweets!

Q1:

Question 1 #ASEchoJC

ASE  
American Society of  
Echocardiography  
ESTABLISHED 1988

## What are common echocardiographic findings in acute COVID-19 infection?

12/19/23 @Kirkpa1 @mswami001 @DavidWienerMD @EGarciaSayan @NadeenFaza

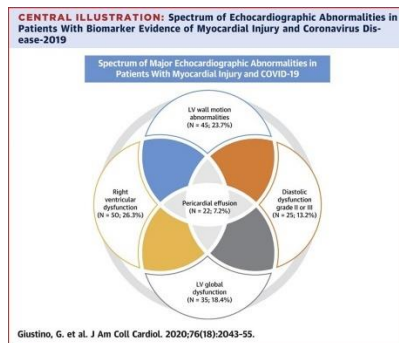
### A1 Notable Responses:

@EGarciaSayan: Question 1 #ASEchoJC:

What are common echocardiographic findings in acute COVID-19 infection?

@EGarciaSayan: LV & RV dysfunction, wall motion abnormalities, diastolic dysfunction, and pericardial effusion are common in patients with #COVID19 and myocardial injury. See @JACCJournals paper by Giustino et al:

<https://sciencedirect.com/science/article/pii/S073510972036589X#undfig2>



@iamritu: LV or RV dysfunction

acute coronary syndrome with LV dysfunction

Stress (takotsubo) cardiomyopathy

Myocarditis

II GIF

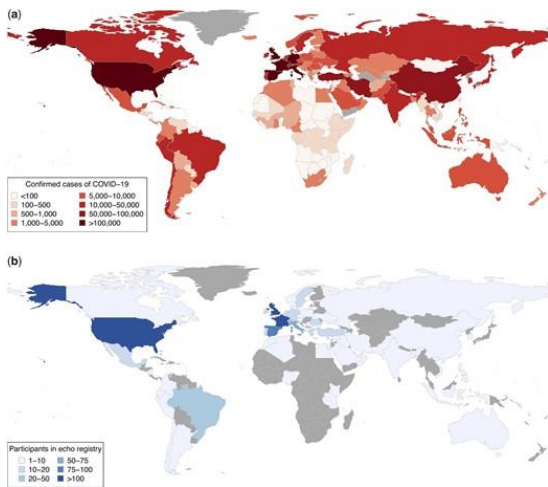
► GIF

**@NadeenFaza:** In acute #COVID19 infection use #EchoFirst to check

- ✓ LV and RV function
- ✓ Pericardial effusion
- ✓ US be used to image the lungs esp prior to CT being performed

**@iamritu:** Saw #McConnell sign with RV involvement early in #Covid19

**@mswami001:** 55% of the examined cohort in this study had echo abnormalities:  
<https://academic.oup.com/ehjcardimaging/article/21/9/949/5859292?login=false>



**@mswami001:** LV dysfunction most common (39%) plus a host of other issues

**@DavidWienerMD:** #COVID can cause:

LV systolic dysfunction (ACS, stress CM, myocarditis, MIS)

LV diastolic dysfunction

RV dysfunction including PHRN and Cor pulmonale

Pericardial effusion

**@EGarciaSayan:** What are common echocardiographic findings in acute COVID-19 infection?

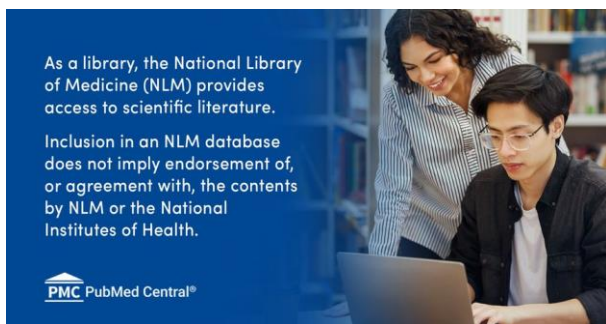
@DavidWienerMD reviewed the variable #EchoFirst findings in #COVID19 infections, including LV systolic & diastolic dysfunction, RV dysfunction, pericardial effusion.

**@Kirkpatj1:** Great question! Many findings center on right heart findings, likely related to effect of lung pathology, but myocarditis, stress cardiomyopathy and worsening of underlying diseases happen. Cardiac findings common and a bad prognostic sign in initial wave.

**@EGarciaSayan:** What are common echocardiographic findings in acute COVID-19 infection?  
@Kirkpatj1 discusses frequency and prognostic value of cardiac findings on #COVID19 infection

**@NadeenFaza:** How prevalent are LV thrombi in this patient population?

**@iamritu:** High esp in hospitalized patients with acute Covid19  
<https://www.ncbi.nlm.nih.gov/pmc/articles/PMC8715711/>



**@EGarciaSayan:** What are common echocardiographic findings in acute COVID-19 infection? @mswami001 highlights global study demonstrating >50% of #COVID19 patients had #EchoFirst abnormalities. <https://academic.oup.com/ehjcardimaging/article/21/9/949/5859292?login=false>

## Question 2:

**Question 2 #ASEchoJC**  
**What are the characteristic echocardiographic findings of post-COVID-19 vaccine myocarditis?**  
12/19/23 @Kirkpatj1 @mswami001 @DavidWienerMD @EGarciaSayan @NadeenFaza

**ASE**  
American Society of  
Echocardiography  
Event Dates Listed

### A2 Notable Responses:

**@EGarciaSayan:** Question 2 #ASEchoJC:

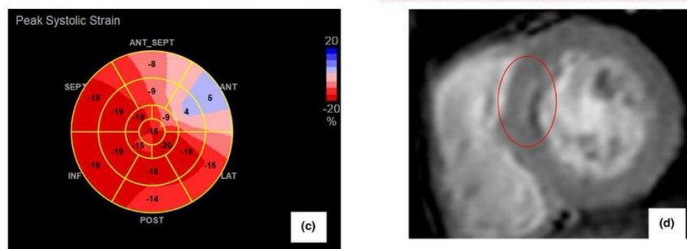
What are the characteristic echocardiographic findings of post-COVID-19 vaccine myocarditis?

**@iamritu:** Uncommon by #echofirst

may see rarely by #whyCMR as incidental inflammation with no clinical sequelae

**@Slwa23288585:** This one 🤔

<https://pubmed.ncbi.nlm.nih.gov/36513963/>



**FIGURE 1** (a) Electrocardiogram (ECG) findings on admission revealed II, III, aVf, V5, and V6 ST abnormalities. (b) One month after discharge, the ST change on ECG was improved. (c) Two-dimensional speckle tracking findings by echocardiography revealed a global longitudinal strain as -13% and abnormal wall motion in the anteroapical at the base. (d) Cardiac MRI revealed early gadolinium enhancement in the anteroapical at the base (red circle).

**@EGarciaSayan:** What are the characteristic echocardiographic findings of post-COVID-19 vaccine myocarditis? @Slwa23288585 highlights pediatric case and the role of LV strain

**@mswami001:** Rare and infrequent, but seen most often in males 16-18 within 3 days of 2nd vax dose

**@mswami001:** WASE study from @ASE360 also reviewed post #COVID19 myocarditis








**@DavidWienerMD:** Link to the #WASE #COVID study

[https://onlinejase.com/article/S0894-7317\(21\)00817-8/fulltext](https://onlinejase.com/article/S0894-7317(21)00817-8/fulltext)

**@DavidWienerMD:** Lung imaging is a rapid POC modality for pulmonary pathology in COVID.

Link to "Lung Ultrasound Imaging: A Primer for Echocardiographers" from which the graphic was made in

@JournalASEcho: <https://bit.ly/3RM4kUO>

	Normal		COVID-19	
Pleural lines	Smooth		Thick, irreg, fragmented	
Lung sliding	Present		Decreased	
A vs. B lines	A lines		B lines	
Subpleural consolidation	Absent		Present	


J Am Soc Echocardiogr 2021;34:1231-41

**@EGarciaSayan:** What are common echocardiographic findings in acute COVID-19 infection? It's not about the heart! @DavidWienerMD highlights the importance of learning the key parameters of lung ultrasound. Understand difference between A-lines & B-lines

[https://onlinejase.com/article/S0894-7317\(21\)00652-0/fulltext](https://onlinejase.com/article/S0894-7317(21)00652-0/fulltext)

### Question 3:

**Question 3 #ASEchoJC**

 **ASE**  
AMERICAN SOCIETY OF  
ECHOCARDIOGRAPHY  
Save Lives. Every Day.

**Can long COVID-19 syndrome  
result in cardiac  
abnormalities detected by  
echocardiography?**

12/19/23 @Kirkpatj1 @mswami001 @DavidWienerMD @EGarciaSayan @NadeenFaza

### A3 Notable Responses:

**@EGarciaSayan:** Question 3 #ASEchoJC:

Can long COVID-19 syndrome result in cardiac abnormalities detected by echocardiography?

**@iamritu:** Tough to tell who recovered depending on baseline Fxn & which pt population studied hospitalized vs ambulatory patients, mild vs severe acute disease, and how long the follow up period was

**@mswami001:** Often hard to distinguish de novo heart disease from pre-existing myocardial disease


**@NadeenFaza:** Further studies are needed for characterization of echo features of long #COVID19.

**@mswami001:** Important also to differentiate "long covid syndrome" from "post-covid syndrome"

**@mswami001:** With almost everyone being exposed to #COVID19, cardiac disease from covid in patients is tricky...

**@Kirkpatj1:** We need more data! Studies have been limited and heterogenous to date. But we should have more data on how long abnormalities persist. It may depend a great deal on underlying pathology and perhaps even effects on other organ systems.

**@durstenfeld:** In our JCI insight paper, Long COVID was not associated with echo abnormalities except possibly pericardial effusions (not statistically sig): <https://pubmed.ncbi.nlm.nih.gov/35389890/>



As a library, the National Library of Medicine (NLM) provides access to scientific literature.


Inclusion in an NLM database does not imply endorsement of, or agreement with, the contents by NLM or the National Institutes of Health.

**Pub Med**®



#### Question 4:

Question 4 #ASEchoJC



ASE  
American Society of  
Echocardiography  
Heart. First. Last.

### What strategies are implemented to decrease the risk of viral transmission during a transthoracic echocardiogram?






12/19/23 @Kirkpat1 @mswami001 @DavidWienerMD @EGarciaSayan @NadeenFaza

#### A4 Notable responses

@EGarciaSayan: Question 4 #ASEchoJC:

What strategies are implemented to decrease the risk of viral transmission during a transthoracic echocardiogram?

@EGarciaSayan: The new #COVID19 guideline update recommends specific strategies to minimize transmission and protect #EchoFirst staff based on a disaster-response planning model involving 3 phases.

	Conventional	Contingency	Crisis
 Indications	• AUC	• Defer non-urgent	• Only emergent, likely to survive
 Transmission control	• Standard	• Limited protocol • No ECG	• Very limited protocol, or • POCUS* only
 POCUS/CCE	• Standard	• Use to triage full exam • Remote guidance	• POCUS* only • Decision without imaging
 Alternative imaging	• Standard	• CT/CMR/nuclear in place of TEE	• Decision without imaging
 Training	• Standard/hybrid	• Remote as default • Simulators	• Remote only

@mswami001: This is an extremely useful graphic to illustrate differing strategies based on situation:

@iamritu: Bring #UEA with for every patient as a means to preserve #PPE & improve evaluation of LV function. Patients may have difficult suboptimal windows don't want sonographers taking too much time to optimize images Give #UEA get your images & get out of the room

@mswami001: And keep the #UEA ready to administer

@rajdoc2005:        Agree!!

Catching up on these posts now!

@mswami001: \* minimal contact

\* No EKG dots if not needed (use timed capture)

\* PPE

\* Limited exam/images

@NadeenFaza:

✳ Vaccination of medical personnel

✳ ECGs can be imported from telemetry








- ✳️ UEAs should be readily available, when needed
- ✳️ Measurements can be done after image acquisition
- ✳️ Limited studies should be performed, if they can answer the clinical question

**@EGarciaSayan:** What strategies are implemented to decrease the risk of viral transmission during a transthoracic echocardiogram?

**@DavidWienerMD:** Well said @NadeenFaza. And these "hacks" can be used during ordinary times and make image acquisition and lab function more efficient

**@DavidWienerMD:** Many labs vary their response following a standard disaster planning model

	Conventional	Contingency	Crisis
 Indications	• AUC	• Defer non-urgent	• Only emergent, likely to survive
 Transmission control	• Standard	• Limited protocol • No ECG	• Very limited protocol, or • POCUS* only
 POCUS/CCE	• Standard	• Use to triage full exam • Remote guidance	• POCUS* only • Decision without imaging
 Alternative imaging	• Standard	• CT/CMR/nuclear in place of TEE	• Decision without imaging
 Training	• Standard/hybrid	• Remote as default • Simulators	• Remote only

\*POCUS /CCE performed by treating team with simple machines to reduce number of individuals exposed and exposure duration and safeguard limited sonographer resources.

**@Kirkpatj1:** PPE, vaccines, etc, but also practical means to reduce exposure time: time-based acquisitions without ECG leads, no measurements on machine in room, etc, planned focused/limited studies. but can also defer, if appropriate, until COVID –

**@NadeenFaza:** Key points from the updated @ASE360 COVID-19 guidelines!

#EchoFirst in acute infections 🦠, post vaccine myocarditis 💧, and long COVID19 syndromes.

## Key Points

- Echocardiography in acute COVID-19 infection should assess LV and RV systolic function, pericardial effusion, and lung imaging (particularly in the setting of an unremarkable CXR when no CT scan has been performed).
- Echocardiography to evaluate suspected myocarditis from COVID-19 or postvaccination should assess LV and RV systolic function, wall thickness, diastolic function, GLS, and pericardial thickness and effusion with imaging for constriction as clinically indicated.
- Echocardiography in patients with long COVID syndromes requires further study.

**@DavidWienerMD:** Suggested responses to COVID-19 and other crises follow the Institute of Medicine's 3-tier model for crisis standards of care and preparedness

THE CONTINUUM OF CARE: CONVENTIONAL, CONTINGENCY AND CRISIS				
	Effect on Standard of Care	Resource Constrained	Practicing Outside Experience	Focus of Care
Conventional	No	No	No	Patient
Contingency	Slightly	Slightly	No	Patient
Crisis	Yes	Yes	Yes	Population

INSTITUTE OF MEDICINE  
OF THE NATIONAL ACADEMIES  
Advising the nation • Improving health

**@DavidWienerMD:** The on line supplements contain real world examples of #echofirst triage protocols from 3 medical centers in different regions. They can help clinicians prioritize patients and indications

Appendix 1  
Guidance for triage of non-emergent outpatient transthoracic echocardiograms during the Covid-19 pandemic (March 2020)  
Thomas Jefferson University, Philadelphia, PA

Tier	Definition	Effect on patient	Examples	Action
Tier 1a	Low acuity/asymptomatic patient Not life threatening	Results will not affect clinical management or outcome	• All cardiac conditions without change in clinical status, e.g., severe valve disease, pericardial effusion, aortic dissection, pulmonary hypertension, etc.	Postpone study
Tier 1b	Low acuity/asymptomatic patient Not life threatening	Results will not affect clinical management or outcome	• Severe heart failure, symptomatic pulmonary hypertension, etc.	Postpone study
Tier 2a	Intermediate acuity/asymptomatic patient Not life threatening but potential for future morbidity or mortality	Results will affect clinical management or outcome	• Severe aortic stenosis, aortic regurgitation, etc.	Postpone study
Tier 2b	Intermediate acuity/asymptomatic patient Not life threatening but potential for future morbidity or mortality	Results will affect clinical management or outcome	• Severe aortic stenosis, aortic regurgitation, etc.	Postpone study

Appendix 2  
Guidance for triage of non-emergent outpatient transthoracic echocardiograms during the Covid-19 pandemic (April 2020)  
Lyndon B. Johnson General Hospital University of Texas Health

Tier	Definition	Effect on patient	Examples	Action
Tier 1	High acuity/emergent or life-threatening patient Potentially life threatening	Results will affect clinical management or outcome	• New or worsening cardiac condition, e.g., severe valve disease, pericardial effusion, aortic dissection, pulmonary hypertension, etc.	Do not postpone
Tier 2	Intermediate acuity/emergent or life-threatening patient Potentially life threatening	Results will affect clinical management or outcome	• Severe heart failure, symptomatic pulmonary hypertension, etc.	Do not postpone
Tier 3	Low acuity/asymptomatic patient Not life threatening	Results will not affect clinical management or outcome	• All cardiac conditions without change in clinical status, e.g., severe valve disease, pericardial effusion, aortic dissection, pulmonary hypertension, etc.	Postpone study

ECG, electrocardiogram; EF, ejection fraction; HF, heart failure; LVEF, left ventricular ejection fraction; LV, left ventricle; DVT, deep vein thrombosis; RV, right ventricle.

\*Expert consultation refers to advice by an echocardiography attending physician and discussion with the referring health care professional if needed.

Adapted from the American College of Surgeons Executive Faculty Scale (EFS) and EF.

Appendix 2  
Guidance for triage of non-emergent outpatient transthoracic echocardiograms during the Covid-19 pandemic (April 2020)  
Lyndon B. Johnson General Hospital University of Texas Health

Level of urgency	Clinical situation and diagnosis
<b>Green Dot</b> I. Do not delay, or schedule sooner	Intermediate acuity symptomatic patient, high acuity symptomatic or asymptomatic patient, potentially life threatening, results may affect outcomes in <30 days.  Examples: • Severe symptomatic valvular or myocardial disease • New symptoms w/ significant cardiopulmonary disease • Concern for significant pericardial effusion/thrombus • New HF/EF with EF <35% and where decision for ICD is needed • Recent MI or cardiac arrest when follow-up TTE is indicated
<b>Yellow Dot</b> IIA. Delay, but should be future scheduling priority (average ordering physician in Epic, could potentially become urgent)	Intermediate acuity asymptomatic patient, results may affect medium to long term outcomes, potentially higher level of urgency depending on non-cardiac factors.  Examples: • Cardio-oncology patients (diagnosis) not meeting criteria in I • Pregnant patients not meeting criteria in I • Severe valvular or myocardial disease, symptomatic unclear • Prep for urgent surgery (discuss with ordering)
<b>Orange Dot</b> IIB. Delay, but should be future scheduling priority	Intermediate acuity asymptomatic patient, results may affect medium to long term outcomes, level of urgency appears fairly clear from chart review.  • Severe valvular or myocardial disease, clearly asymptomatic per chart review, no echo <1 year • Moderate valvular or myocardial disease, no echo <2 years • Follow-up RV function, PASH in patients with no echo <1 year
<b>Red Dot</b> III. Ok to delay for at least 60 days	Low acuity TTE, potentially inappropriate or uncertain indication, results unlikely to affect medium to long term outcomes.  Examples: • Syncope, low suspicion for cardiac cause • New murmur, asymptomatic • Mild valvular disease • Arrhythmias, asymptomatic • HTN, DM, "prep" for clearly elective surgery

Appendix 3  
Triage of echocardiography procedure orders (January 2022)  
University of Washington, Seattle, WA

Question	If yes
1. Is the indication considered "rarely appropriate" or "inappropriate" by appropriate use criteria?	Cancel
2. Even if appropriate, is the indication "routine"?	Postpone, unless there are extenuating circumstances (e.g., travel from distance or other patient hardships)
3. Can the echocardiogram wait until the patient is out of COVID quarantine?	Postpone
4. Is the order "stat", "emergent", or "urgent"?	Performed with appropriate PPE, limited protocol
5. Is the patient at risk of an adverse event (morbidity, mortality, including ED visit and hospitalization) in the next 2-6 weeks if: • Echocardiographic detection of suspected pathology does not occur? • Echocardiographic diagnosis of the cause of symptoms is not made? • Echocardiographic characterization of known pathology does not occur? • Echocardiographic follow-up of known lesion(s) to assess for worsening is not performed?	Perform
6. Is the exam necessary for the patient to receive a life-sustaining or significant morbidity-reducing intervention in the next 6 weeks (e.g., stress echo prior to organ transplant)?	Perform

COVID, coronavirus disease; ED, emergency department; PPE, personal protective equipment.


Note: TEEs, TEE-DCCV and stress testing will be performed for patients without known or suspected COVID, with appropriate pre-procedure screening and testing.

Note: For patients who are known to have COVID, current guidelines for return to ambulatory care will be applied to outpatient echocardiograms

**@EGarciaSayan:** What strategies are implemented to decrease the risk of viral transmission during a transthoracic echocardiogram? @DavidWienerMD reviewed real-world #EchoFirst triage protocols included in the new #COVID19 guideline update <https://asecho.org/guideline/american-society-of-echocardiography-covid-19-statement-update-lessons-learned-and-preparation-for-future-pandemics/>

## Question 5:

**Question 5 #ASEchoJC**

**ASE**  
AMERICAN SOCIETY OF  
ECHOCARDIOGRAPHY  
Second Edition 2018

**What is the role of Point of Care Ultrasound (POCUS) in the setting of a highly transmissible disease?**

12/19/23 @Kirkpat1 @mswami001 @DavidWienerMD @EGarciaSayan @NadeenFaza

## A5 Notable responses

@EGarciaSayan: Question 5 #ASEchoJC:

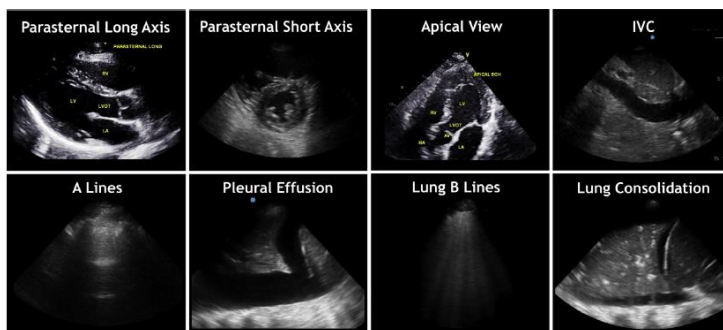
What is the role of Point of Care Ultrasound (POCUS) in the setting of a highly transmissible disease?

@NadeenFaza: 🗝 points from the updated @ASE360 #COVID19 guidelines addressing the use of #POCUS.




### Key Points

- Cardiac and chest POCUS may guide the need for further imaging and limit exposure to as few individuals as possible.
- If cardiac POCUS or CCE answers the clinical question, it is usually not necessary to perform a confirmatory formal echocardiogram.
- Routine cardiac POCUS/CCE application is *not* meant to shift the burden of exposure to infectious agents from echocardiography laboratory personnel to POCUS/CCE users but rather to facilitate best use of resources. Cardiac POCUS should not be performed when CCE or comprehensive echocardiography is clearly indicated.
- An adequate number of POCUS/CCE machines, PACSs that allow uploading of images and the ability of echocardiography laboratory personnel to view the images, adequately trained clinicians, and overall integration into a system of cardiac imaging should be implemented ahead of future pandemics.
- In addition to having clear standards for training and credentialing, a multidisciplinary body that includes representatives from a diverse group of POCUS/CCE experts should be involved in hospital-level decisions to optimize POCUS/CCE integration into clinical care.
- Cardiac POCUS/CCE exams should be formally interpreted, documented, and archived in the medical record.

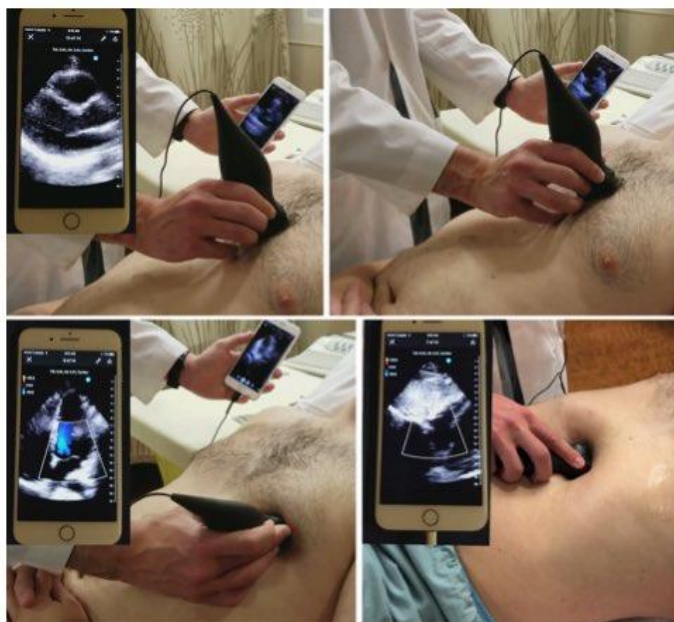@EGarciaSayan: must-read @ASE360 #POCUS statement during #COVID19 by @amerjohri et al provides guidance on cardiopulmonary protocol & device-cleaning checklist. 🗝 [https://asecho.org/wp-content/uploads/2020/06/COVID-POCUS\\_June-2020.pdf](https://asecho.org/wp-content/uploads/2020/06/COVID-POCUS_June-2020.pdf)



@iamritu: Use pocus to triage the need for more testing to reduce exposure time & transmission, specifically targeting pocus to answer the clinical question <https://bit.ly/2UTM4v2>

Table 1. ASE POCUS Protocol in Suspected or Confirmed COVID-19 Infection. A modified POCUS protocol to assist in the assessment of COVID-19 patients includes heart, chest and vessel views.			
COVID19 POCUS Protocol	Structure Imaged	Assessment	Disease Associations
	Left Ventricle	Size, Global and Regional Function	Myocarditis ACS Cardiomyopathy Shock
	Right Ventricle	Size and Function; TR for PASP if available	PE Cardiomyopathy
	Pericardium	Effusion	Tamponade
	Valves	Gross Regurgitation or stenosis	Pre-existing CV disease
	8 or 12 point exam	B Lines (A lines, pleural sliding are normal)	Edema or Pneumonia
		Sub-pleural Consolidation Thickened Pleura	Pneumonia ARDS
		Lobar consolidation with air Bronchograms	Pneumonia ARDS
		Effusion	CHF
	JVP or Subcostal IVC	Fluid Status	CHF, hypovolemia
	*/- Leg Veins*	2 point compression*	DVT

\*Leg veins may be assessed if the operator has training in this technique, clinical suspicion exists, and the sonographer is not available.  
ACS, acute coronary syndrome; TR, tricuspid regurgitation; PASP, pulmonary artery systolic pressure; PE, pulmonary embolism; CV, cardiovascular; ARDS, acute respiratory distress syndrome; JVP, jugular venous pulsation; IVC, inferior vena cava; CHF, congestive heart failure; DVT, deep vein thrombosis.



**@mswami001:**

- \* Helpful in ICUs
- \* Rapid diagnostics
- \* Existing trained ICU staff (additional staff may not be needed)
- \* Limited exam and pertinent info
- \* Machines at POC readily available

**@mswami001:** ASE Statement on Point-of-Care Ultrasound during the 2019 Novel Coronavirus Pandemic (<http://asecho.org>) [https://asecho.org/wp-content/uploads/2020/06/COVID-POCUS\\_June-2020.pdf](https://asecho.org/wp-content/uploads/2020/06/COVID-POCUS_June-2020.pdf)

**@mswami001:** Valuable lessons learned during pandemic. Centers prepared with POCUS capability were better able to tackle ICU imaging needs

**@EGarciaSayan:** @mswami001 reviews the role of Point of Care Ultrasound (POCUS) in critical care in the setting of a highly transmissible disease such as #COVID19

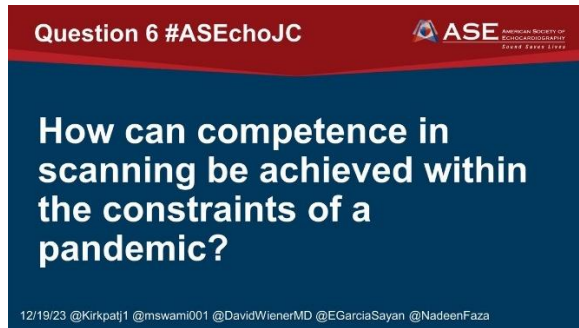
**@Kirkpatj1:** Important not to shift exposure on to POCUS users. Need to assess the situation and be efficient about exposure. And depends on who is capable of doing cardiac POCUS and how difficult patient is to scan.

**@iamritu:** important point from @Kirkpatj1

**@EGarciaSayan:** What is the role of Point of Care Ultrasound (POCUS) in the setting of a highly transmissible disease? @Kirkpatj1 highlights the importance of not shifting burden and exposure risk to #POCUS users

**@mswami001:** Key point. ICU staff frequently felt that POCUS use was being shifted to them to avoid exposure yet with the risk of an insufficient exam. Hard choices...

## Question 6:



## A6 Notable responses

**@EGarciaSayan:** Question 6 #ASEchoJC:

How can competence in scanning be achieved within the constraints of a pandemic?

**@iamritu:** hybrid learning models are 🔑

in-person

simulation

Asynchronous online education

Also extending amount of time allowed to acquire requisite number of cases may help

**@EGarciaSayan:** @iamritu highlights some examples of strategies for training and achieving competence in #EchoFirst during a pandemic.

**@Slwa23288585:**

👉 ハイブリッド学習モデル 🔑

👉 対面

👉 シミュレーション

👉 非同期オンライン教育

yes 🤔

**@mswami001:** Especially simulation in #echofirst with disease modules with automated feedback.

**@mswami001:** #ArtificialIntelligence in #echofirst can also help

**@mswami001:** Really hard question. Competence versus simple observation. Limited contact may mean limited learning...

**@EGarciaSayan:** @mswami001 highlights the challenges in #EchoFirst scanning training & competence in the setting of a pandemic.

**@mswami001:** Remote learning may diminish learning quality, but likely better than no contact at all...

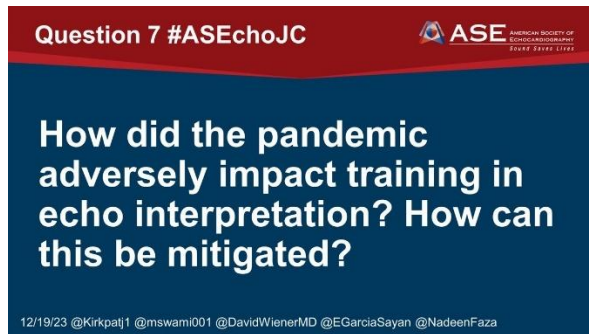
**@DavidWienerMD:** Training in #echofirst can take advantage of complementary pathways to achieve initial and continuing competence. The pandemic made us think out of the 📺 about sonographers and physician training

	In person didactics	Virtual didactics	Texts and E-learning	Hands on instruction and evaluation	Virtual instruction and evaluation	Simulator feedback	Written examinations
Medical Knowledge	✓	✓	✓	NA	NA	NA	✓
Patient Care and Procedure Skills	✓	✓	✓	✓	✓	✓	✓

**@EGarciaSayan:** @DavidWienerMD reviews different pathways and tools to achieve #EchoFirst training & competence for physicians and sonographers during a pandemic



## Question 7:



### A7 Notable responses

**@EGarciaSayan:** Question 7 #ASEchoJC:

How did the pandemic adversely impact training in echo interpretation? How can this be mitigated?

**@mswami001:** Numbers not achieved for certification...

**@EGarciaSayan:** Good point @mswami001. Both certification and recertification, in particular for TEE and stress echo (depending on lab volume) could have been impacted. Same for lab accreditation, though @IACaccred was extremely accommodating in those years given the challenges.

**@DavidWienerMD:** Fortunately, @NBE\_96 and @ABIMcert were flexible and extended the time during which certifiers or recertifiers could submit numbers

**@iamritu:** restrictions during pandemic & cyclical surges forced us to find alternatives like remote case review, using online educational resources ie @ASE360 Learning Hub Hands-on scanning w remote supervision & feedback & using clinical simulators even tele proctoring

**@EGarciaSayan:** @iamritu highlights creative #EchoFirst educational opportunities that developed during the #COVID19 pandemic

**@mswami001:** Limited exams and limited exposure to disease population during the height of the pandemic reduced exposure to a comprehensive spectrum of diseases that would otherwise have been seen

**@DavidWienerMD:** When we were isolating during the peak of the pandemic, the fellows and faculty would log onto the PACS remotely and do interpretations on Zoom

**@SIwa23288585:** Japan too 🙄

**@NadeenFaza:** What strategies can be implemented to decrease the risk of #COVID19 infection spread during a #TEE? Key points 🔑 from the updated @ASE360 guidelines! Knowledge is power!




## Key Points

- The type of PPE applied in specific cases will depend on local institutional policy and resources.
- Vaccination is one of the most effective medical countermeasures for mitigating a pandemic and its devastating effects. COVID-19 and seasonal flu vaccines help reduce the severity of illness with infection and lower the likelihood of spreading viruses to vulnerable populations.
- Exemptions and decisions regarding assignment of unvaccinated staff will depend on local institutional policies.
- Nonpharmacological and behavioral changes that slowed the spread of COVID-19 also impacted the spread of endemic respiratory viruses.
- A limited study should be performed, with images specifically targeted at answering the clinical question and, for de novo cases, addressing the most common expected findings.
- The ECG should be imported from the patient's telemetry system where possible or by using time-based acquisitions.
- Measurements should not be performed at the time of the acquisition.
- UEAs should be readily available, as needed.
- Multimodality imaging may be considered an acceptable alternative to TEE and exercise stress echocardiography in certain circumstances.
- Transporting patients through the hospital, rather than performing a bedside echocardiogram test, may risk broader exposure.
- Dobutamine stress echocardiogram may provide the least exposure risk of any stress test modality.

**@EGarciaSayan:** What strategies are implemented to decrease the risk of viral transmission during a transthoracic echocardiogram?

## Question 8:

**Question 8 #ASEchoJC**

 **ASE**  
AMERICAN SOCIETY OF  
ECHOCARDIOGRAPHY  
Heart. Brain. Life.

**What are the indications for the performance of a TEE exam in a COVID-19-positive patient? How can the risk be minimized?**

12/19/23 @Kirkpalj1 @mswami001 @DavidWienerMD @EGarciaSayan @NadeenFaza

## A8 Notable responses

**@EGarciaSayan:** Question 8 #ASEchoJC:

What are the indications for the performance of a TEE exam in a COVID-19-positive patient? How can the risk be minimized?

**@iamritu:** <https://bit.ly/472Eujz>

Aerosolization highest during TEE of nonintubated patients

But needed to identify mechanism of shock, assess preload w respirophasic variation SVC diameter, stroke volume changes after initiating or titrating vasopressors #ASEchoJC

↓ risk by only doing TEE if it will change management

**@mswami001:** Very few indications for TEE in a #covid pos patient over a TTE. Also, fundamental difference between ICU room and operating room in terms of air handling.


**@mswami001:** OR designed to have positive pressure. ICU rooms have negative pressure. Doing a TEE in an OR and ICU have different implications w.r.t. aerosolization risk

**@mswami001:** Aerosol precautions since patient often not intubated (unlike intraop) and operator is close to airway with cough potential

**@DavidWienerMD:** One lesson I learned and implement to this day is to wear an N95 for AGPs. I'm on the inpatient consult service now during virus season and can't begin to count how many patients test positive for COVID or flu...2 days after I see them

## Question 9:

Question 9 #ASEchoJC

 ASE  
AMERICAN SOCIETY OF  
ECHO-CARDIOGRAPHY  
EST. 1988

# What is the role of CT and CMR in cardiovascular imaging during a pandemic?

12/19/23 @Kirkpatj1 @mswami001 @DavidWienerMD @EGarciaSayan @NadeenFaza

## A9 Notable responses

**@EGarciaSayan:** Question 9 #ASEchoJC:

What is the role of CT and CMR in cardiovascular imaging during a pandemic?

**@EGarciaSayan:** The new #COVID19 guideline update recommends the use of alternative imaging modalities for specific indications during a pandemic. 🙌 Minimize the risk of aerosolization by avoiding TEE or exercise stress when other modalities are appropriate.

Table 3 Alternative imaging modalities for specific indications		
Indication	Modality	Advantages and disadvantages
LAA	CT	Expertise in CT image acquisition and interpretation, especially delayed phase imaging, is essential to optimizing the positive predictive value of CT for detecting LAA thrombus. <sup>7,6</sup>
Valvular heart disease: <ul style="list-style-type: none"><li>• Planning transcatheter valve implantation procedures</li><li>• Evaluation of prosthetic valve dysfunction</li><li>• Evaluation of endocarditis</li></ul>	CT	Due to the lower temporal resolution of CT compared to TEE, small, highly mobile vegetations may be missed. <sup>7</sup> Evaluation of right-sided valves is more technically challenging.
• Quantification of valvular regurgitation	CMR	Role in excluding valvular lesions or vegetations is more limited. <sup>7,8</sup>
• Quantification of chamber size and systolic function		
Detection of infections involving prosthetic valves and cardiovascular implantable electronic devices <sup>9,10</sup>	18-FDG PET <sup>7,9</sup>	
Congenital and structural heart disease	CMR	Role in detecting small patent foramen ovale is more limited. <sup>6,9</sup>
Procedural planning		
Evaluation of chamber size and flows. <sup>10,11</sup>		
Ischemic heart disease	<ul style="list-style-type: none"><li>• Pharmacologic stress echocardiography<sup>12</sup></li><li>• CCTA</li><li>• Pharmacologic nuclear myocardial perfusion</li><li>• CMR perfusion</li></ul>	Lower risk of aerosol generation than with exercise
Cardiomyopathy and myocarditis	CMR <sup>6,14,6</sup>	Can detect COVID and COVID vaccine myocardial inflammation

**@mswami001:** Must also balance resource availability and patient transport when critically ill

**@iamritu:** #Yessct important in #ACS do to r/o CAD & #myocarditis presentations overlap: cath only if +CTA

Also many false negative PCR early in acute disease, use #Yessct to confirm if CXR negative

#WhyCmr key for myocarditis & microvascular dysfunction

**@Kirkpatj1:** Can play a significant role as alternatives to TEE. Not aerosolizing, but have to remember they require transporting a patient through hospital (with potential for exposure) and need to clean room after. TEE is bedside.

## Question 10:

Question 10 #ASEchoJC

ASE  
AMERICAN SOCIETY OF  
ECHOCARDIOGRAPHY  
FOUNDED 1979

**What are key lessons learned from this pandemic related to the practice of echocardiography?**

12/19/23 @Kirkpatj1 @mswami001 @DavidWienerMD @EGarciaSayan @NadeenFaza

## A10 Notable responses

@EGarciaSayan: Question 10 #ASEchoJC:

What are key lessons learned from this pandemic related to the practice of echocardiography?

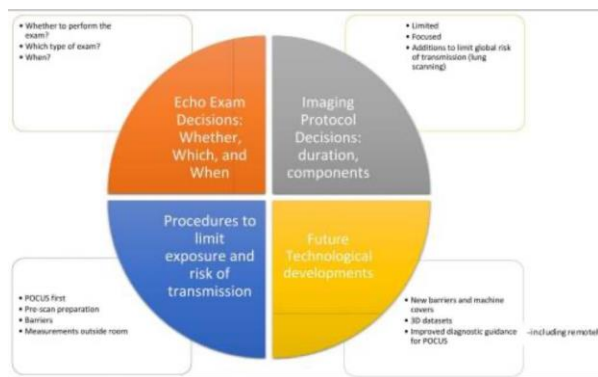
@iamritu:

◆ apply appropriate use criteria and do not do if there's not a new or changed sign or symptom of cvd or will not change management optimize ◆ Use UEAs for endocardial definition

◆ Do measurements offline on workstation afterwards

<https://bit.ly/3ROTQUB>

◆ Pay attention to clinical questions with focused protocols to be safe & effective



@mswami001:

- \* Be adaptable in your lab
- \* Keep hybrid learning options open
- \* Keep PPE and other resources handy
- \* Develop POCUS capability
- \* Consider #AI #echofirst devices to help automate processes

@KalagaraHari: ❤️ #POCUS statement ❤️ .... Along with extending #POCUS 🧑🏻💻 resources to other specialties, especially ICU, ER & Anesthesia !

@mswami001: #echofirst always....

@EGarciaSayan: @mswami001 🗝️ lesson learned from this pandemic related to the practice of echocardiography

**@DavidWienerMD:** 100 😊

#ASEchoJC #echofirst (literally)

**@Slwa23288585:** 🙌🙌🙌

**@iamritu:** #echofirst started in 2017 when we choose it & then @mswami001 started #ASEchoJC so it's been both these #hashtags for over 6 years! <https://x.com/iamritu/status/932642311145754624?s=20>

**@NadeenFaza:**

-Order the right test for the right patient. Follow the appropriate use criteria!

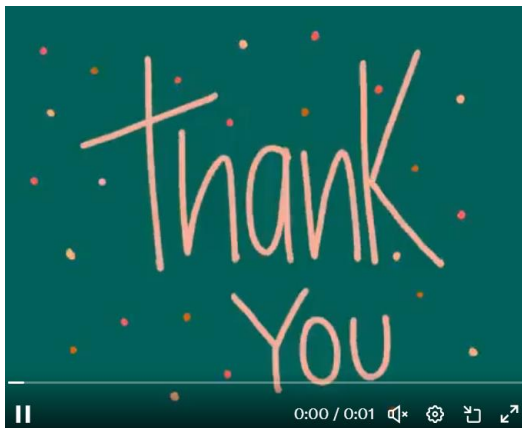-Take excellent care of your patients and echo techs. Minimize the risk of infection during a study. Perform CT/CMR when appropriate.

-Seek virtual #EchoFirst learning opportunities.

**@DavidWienerMD:**

1. Plan ahead for different levels of threat. Triage
2. Protect self/staff
3. Be creative with training, using complementary modalities (POCUS, CCT, CMR)
4. Carry lessons learned forward to help your lab run better during "normal" times

**@EGarciaSayan:** 🎉 And that's a wrap! Thank you all for participating in tonight's #ASEchoJC on X on the new #COVID19 guideline update w/ our guest authors @Kirkpatj1 @mswami001 @DavidWienerMD & co-moderator @NadeenFaza. If you missed anything, you can catch up by following the #ASEchoJC hashtag.



**@DavidWienerMD:** Great discussion as always. Thanks to @EGarciaSayan and @NadeenFaza for making it fun and interesting, and for inviting me

**@EGarciaSayan:** Thanks @DavidWienerMD. Privileged to have you @mswami001 and @Kirkpatj1 join our #ASEchoJC discussion tonight.

**@DavidWienerMD:** It was great working on the guideline with fabulous chairs @Kirkpatj1 and @mswami001 and the other authors. H/T to @ASE360 for its excellent and authoritative guidelines

**@Kirkpatj1:** Great job hosting! Thank you so much.

**@mswami001:** Thanks @EGarciaSayan and @NadeenFaza for hosting and to @ASE360 for a fabulous learning experience #ASEchoJC. Thanks @Kirkpatj1 and @DavidWienerMD and @iamritu!!! What a fab discussion!

**@EGarciaSayan:** Thank you so much @mswami001 for joining our #ASEchoJC and for your thoughtful comments on the new @ASE360 #COVID19 guideline update


**@rajdoc2005:** Sounds like another great #ASEchoJC from @ASE360 Catching up on all the discussion now .... 🧑🧑🧑

**@iamritu:** Thank you for another brilliant #ASEchoJC Time flies when you're on Twitter with all your #echofirst friends discussing this!



**@ase360:** Thank you to EVERYONE who participated in tonight's #ASEchoJC! ❤️

Huge shout-outs to our moderators, @EGarciaSayan and @NadeenFaza, and our guest authors, @Kirkpatj1, @mswami001, and @DavidWienerMD.



@iceman\_ex: Lots of interesting pearls from #ASEchoJC

Am taking notes this morning

